

# Diabetische Retinopathie

Dr.S.A.Koopmans,oogarts

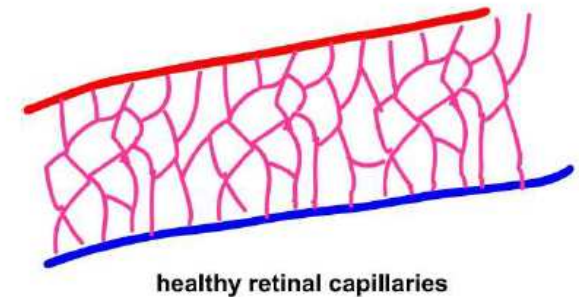
# DRP

- Belangrijke oorzaak slechtziendheid in de westerse wereld.

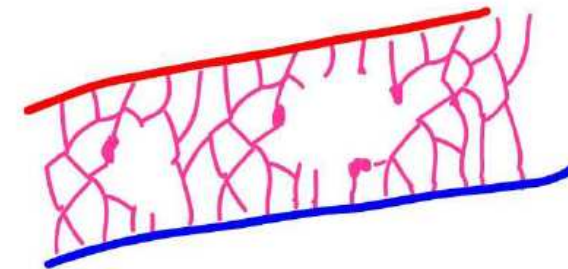
# Diabetische Retinopathie (DRP)

veranderingen in de capillairen  
van het netvlies

- pericytenverlies
- endotheelproliferatie
- verdikking van de  
basaalmembraan



healthy retinal capillaries



diabetic retinal capillaries:  
some are closed off, others form  
dilated segments 'microaneurysms'

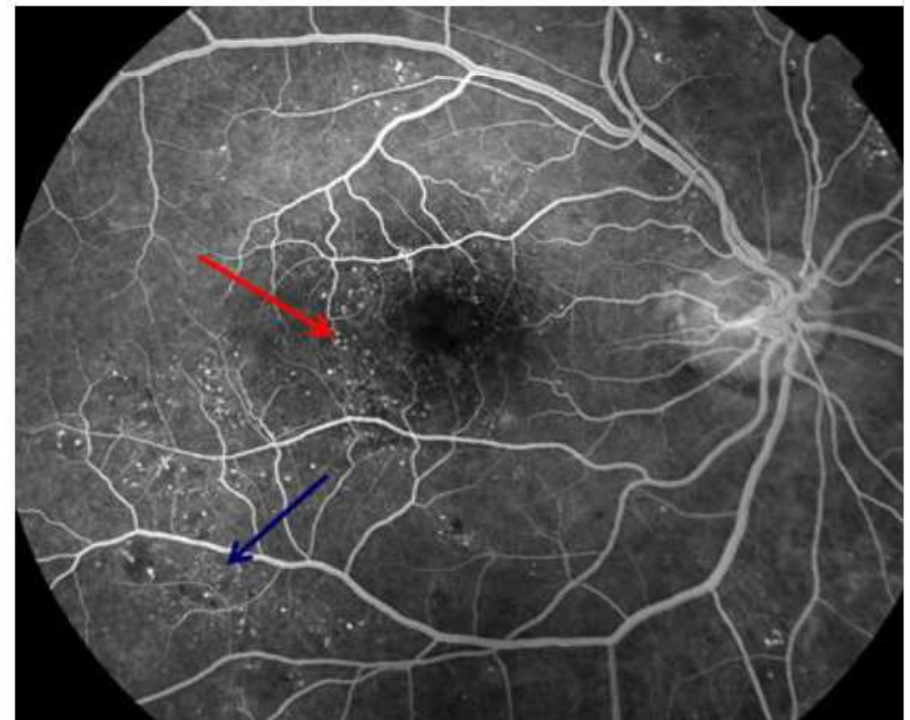
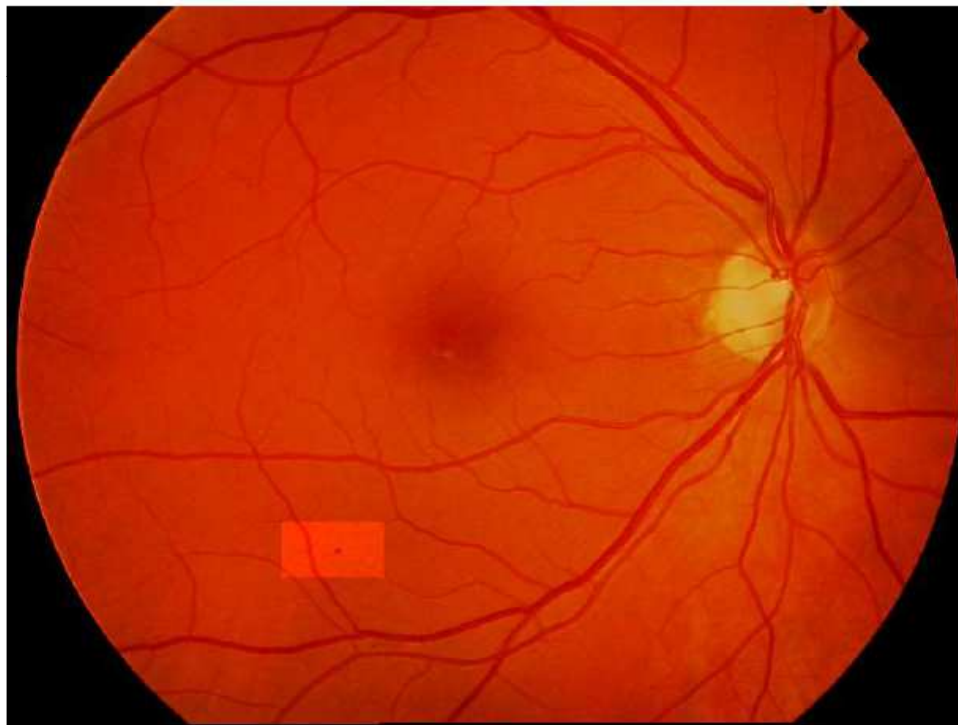
# Diabetische Retinopathie (DRP)

- Vaatlekkage:  
bloedingen, exsudaten, oedeem
- Vaatocclusie: neovascularisaties

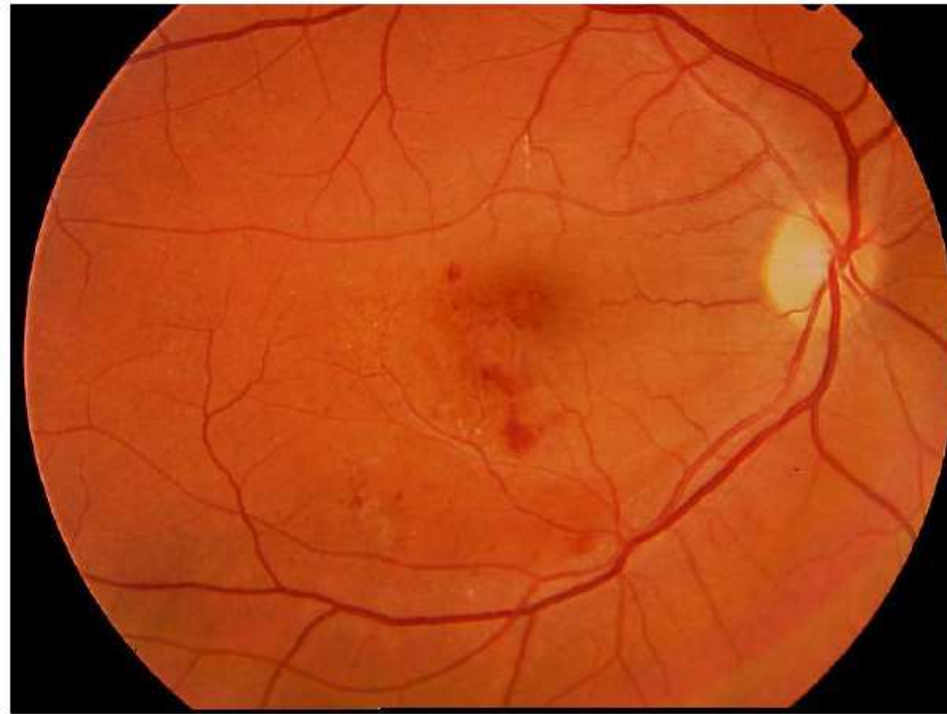
Vaatlekkage

# Eerste zichtbare afwijking van DRP

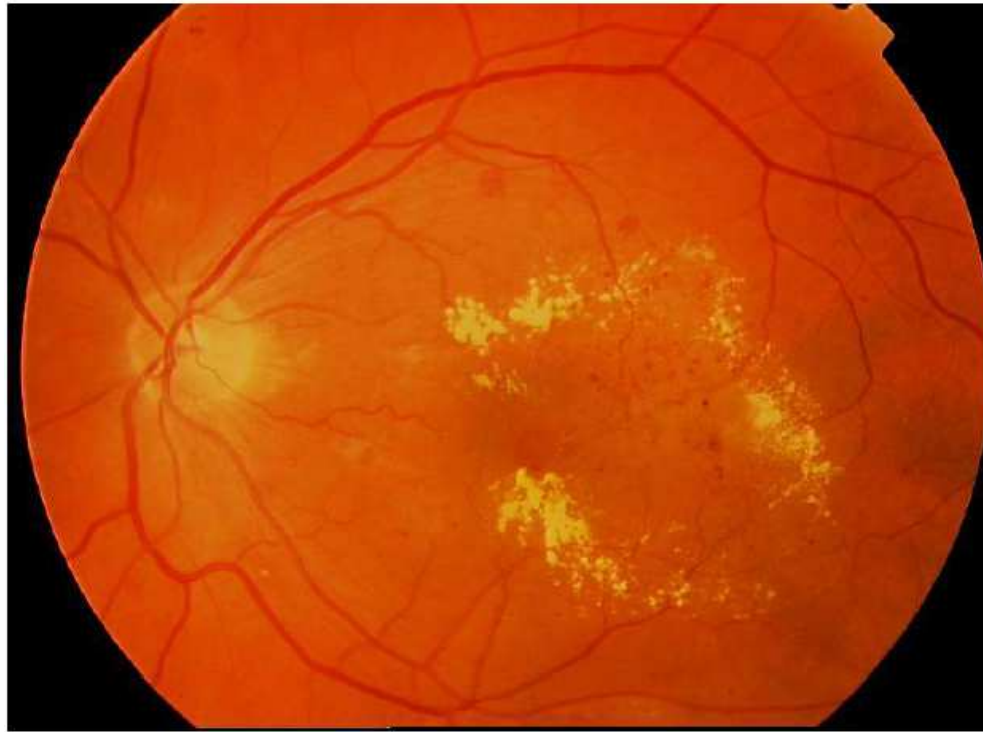
## Microaneurysmata



# Intraretinale bloedinkjes



## Exsudaten en oedeem



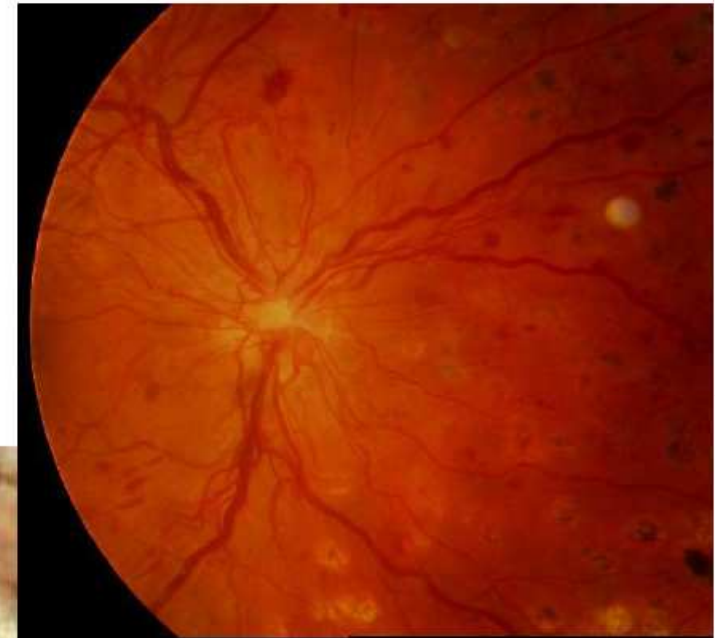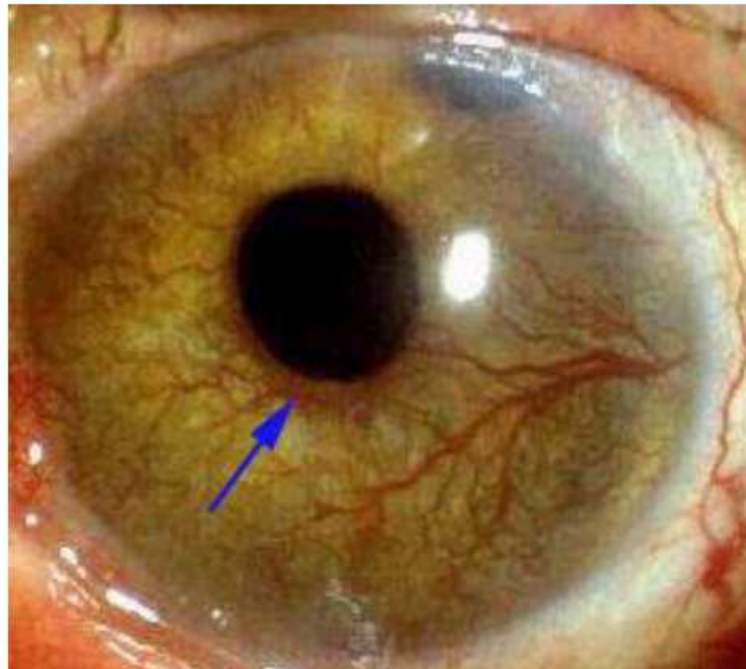


**Vaatocclusie**

# Vaatocclusie → retina ischemie

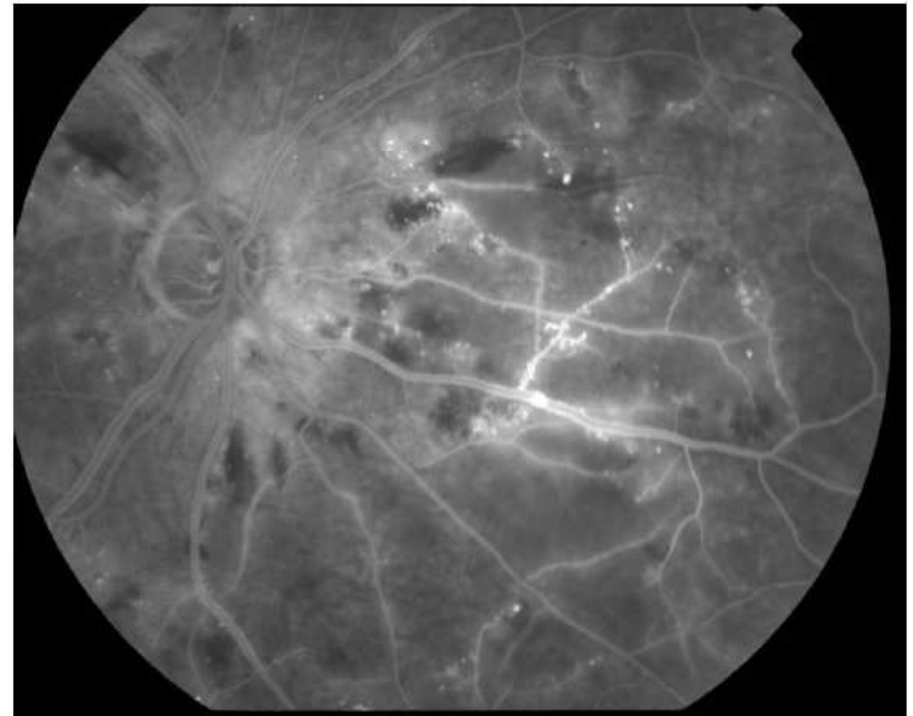
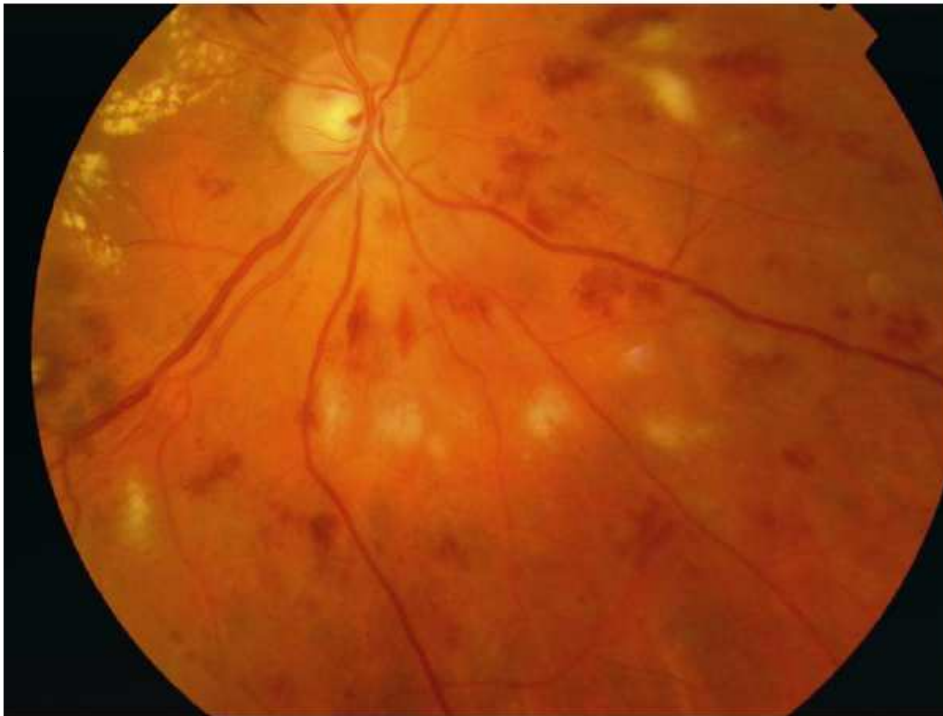
Ischemische retina →  
angiogene factoren →  
neovascularisaties

- papil
- retina
- iris

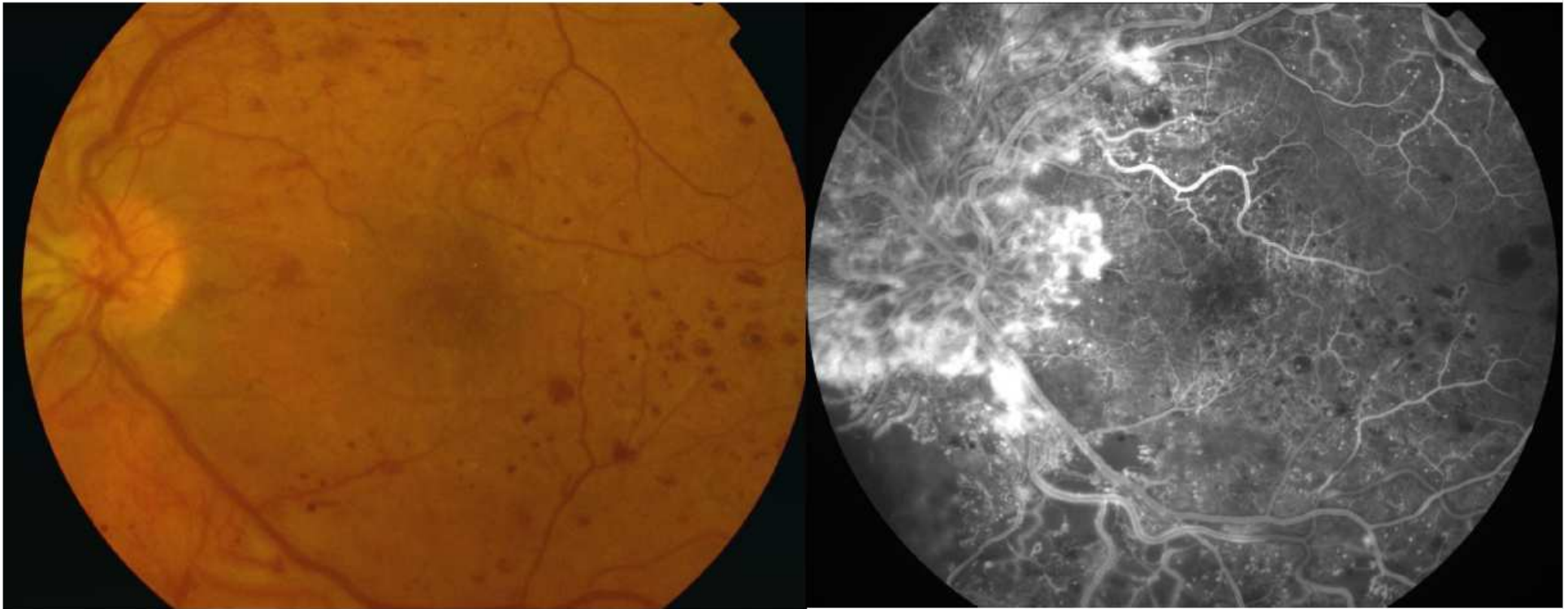


# Cotton wool spots

zachte exsudaten

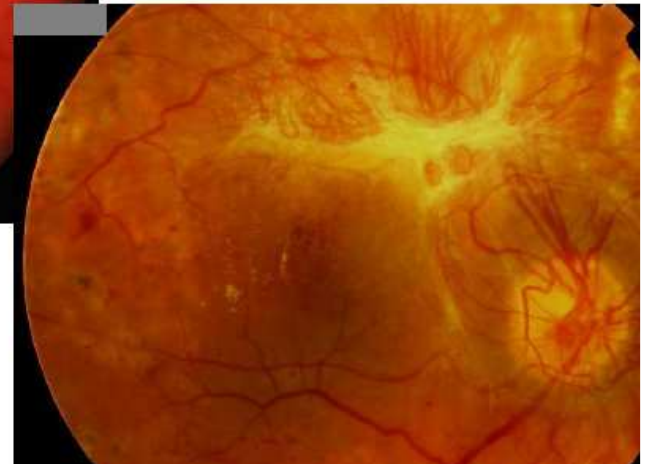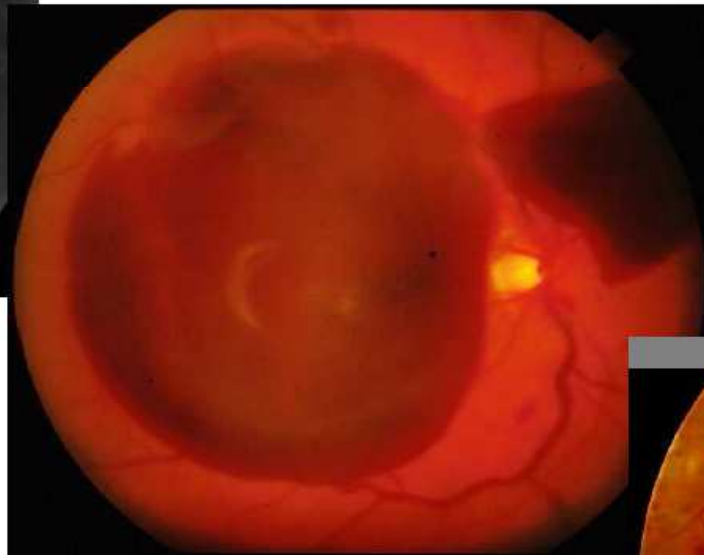
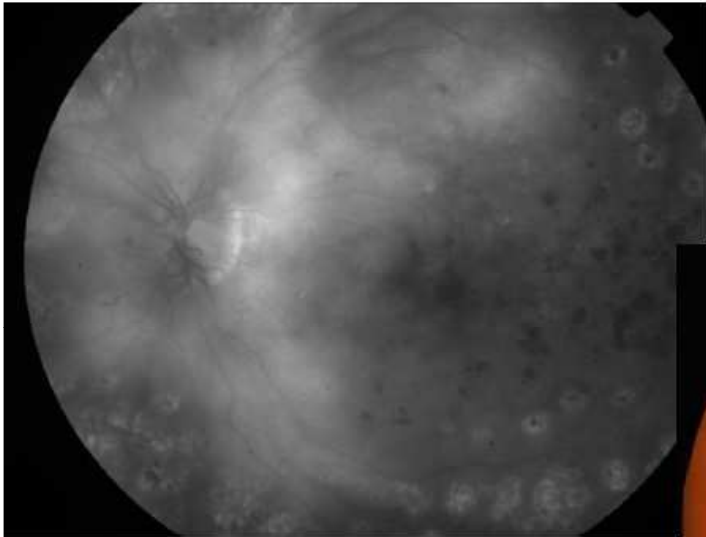


# Neovascularisatie

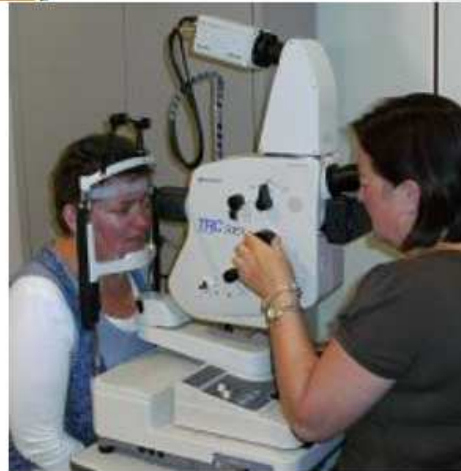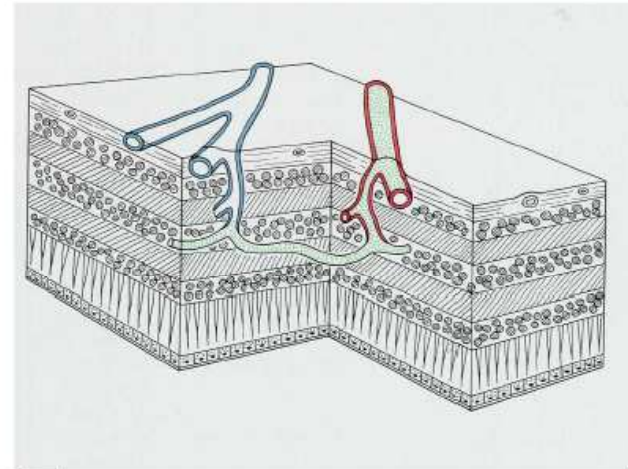
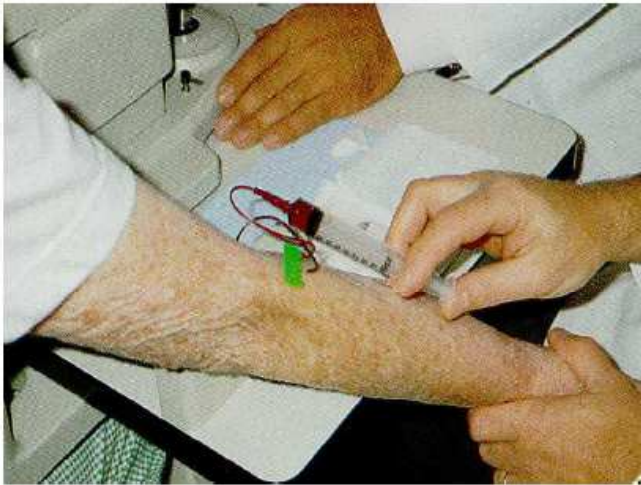


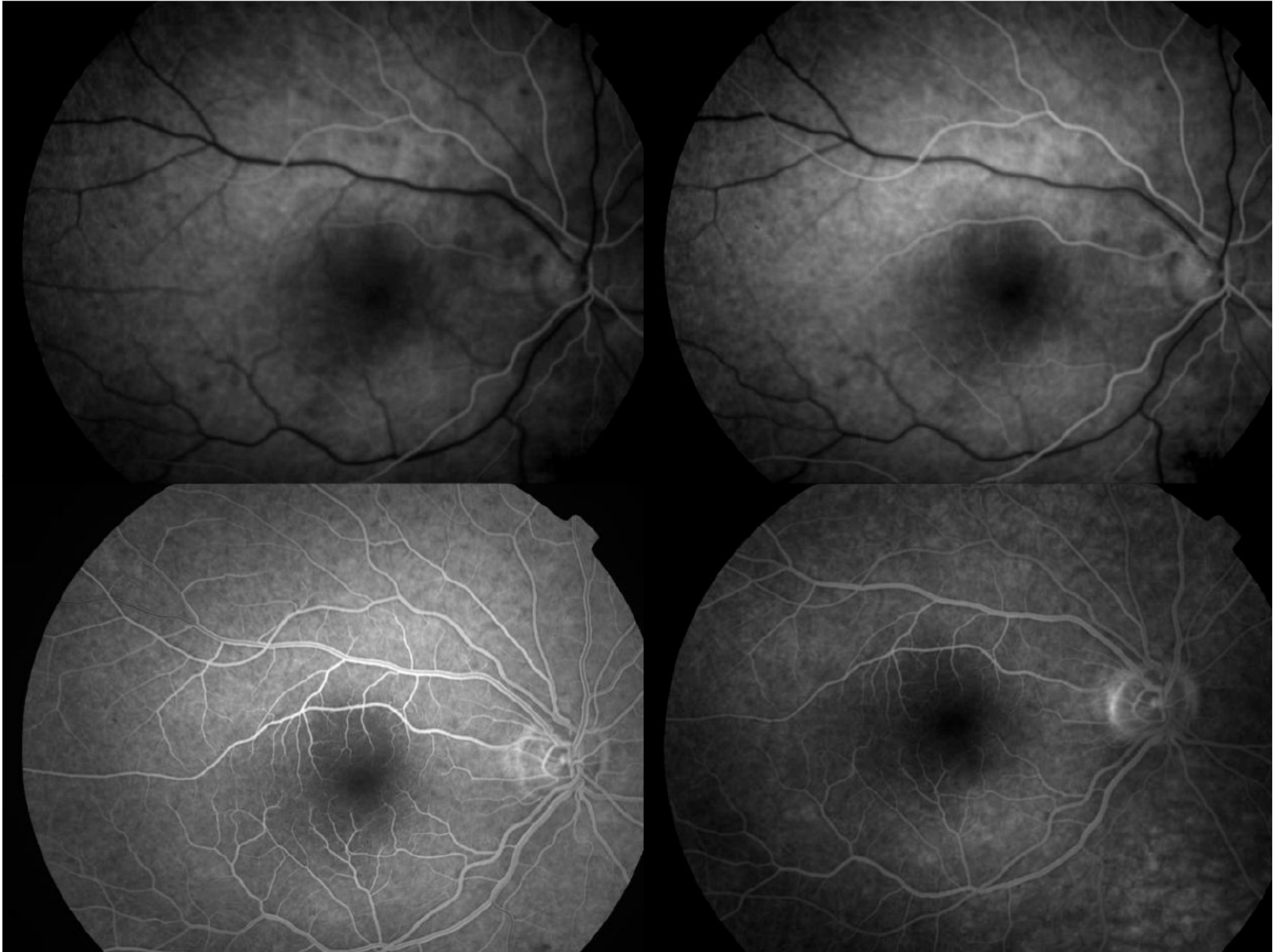# Neovascularisatie

lekkage, bloeding, fibrosering en tractie

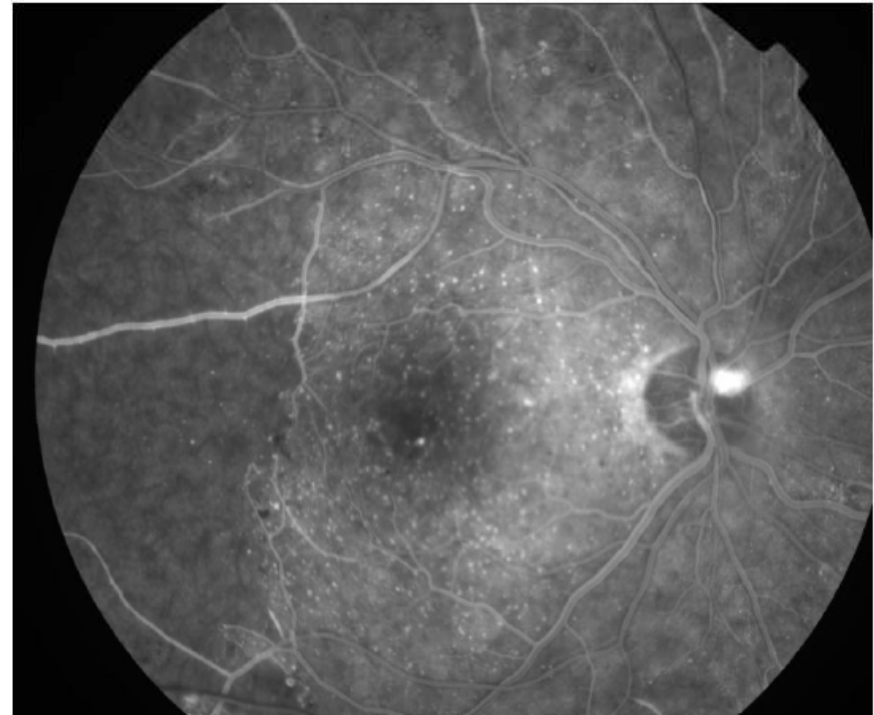



# Fluorescentie angiografie aantonen vaatlekkage en vaatocclusie





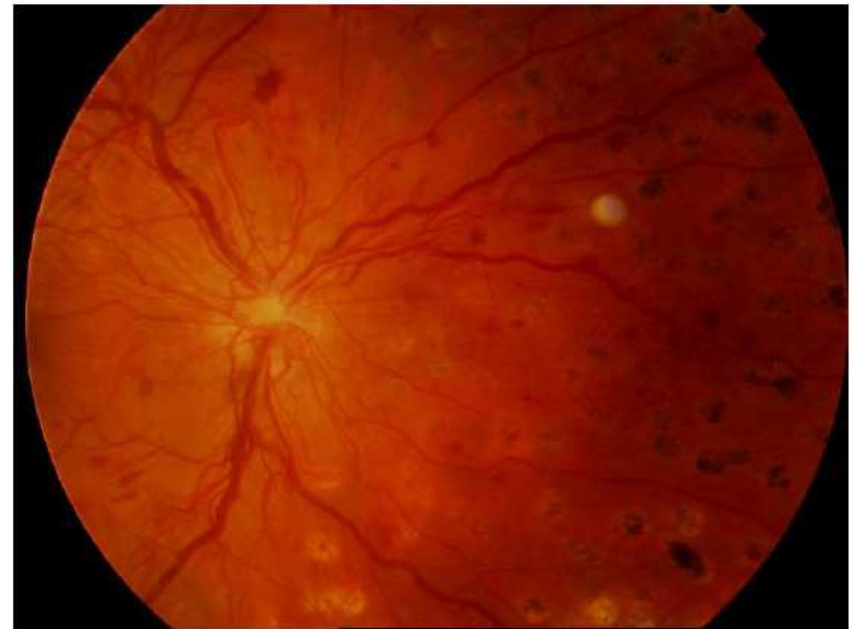
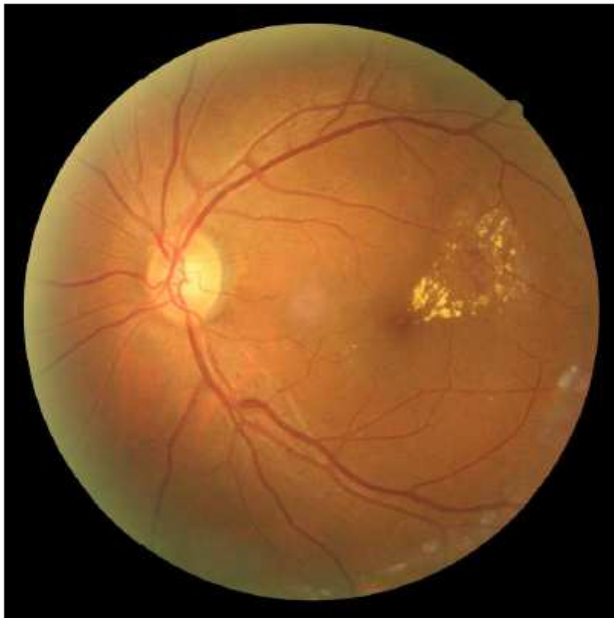
# Vaatlekkage en vaatocclusie





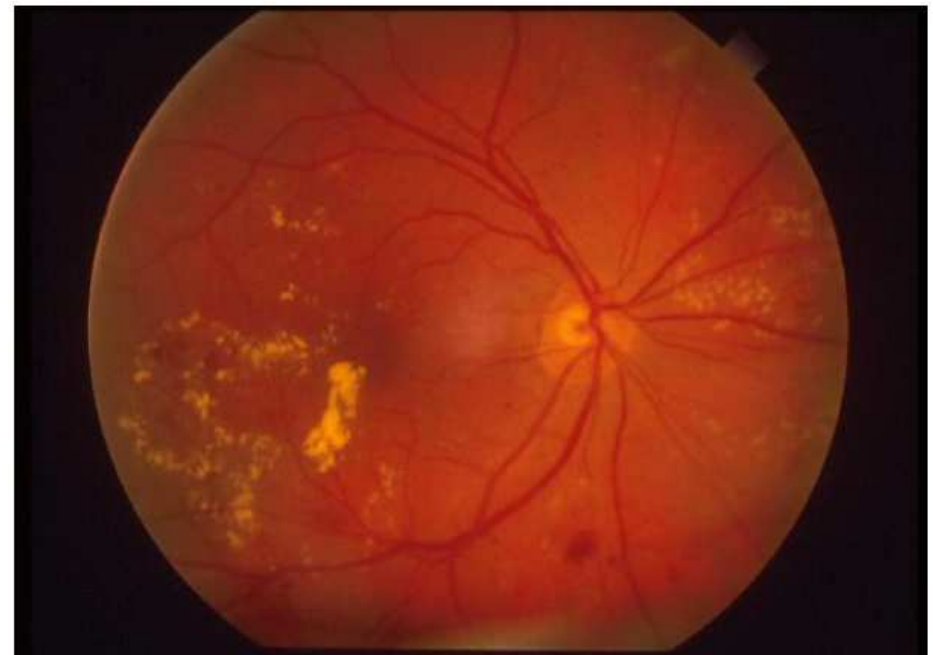# Klassificatie DRP

- Exsudatieve DRP
- Proliferatieve DRP



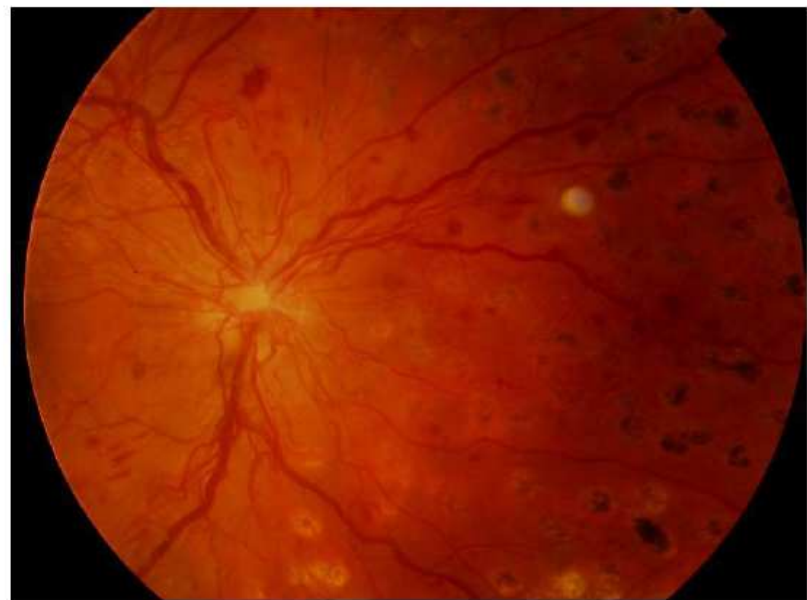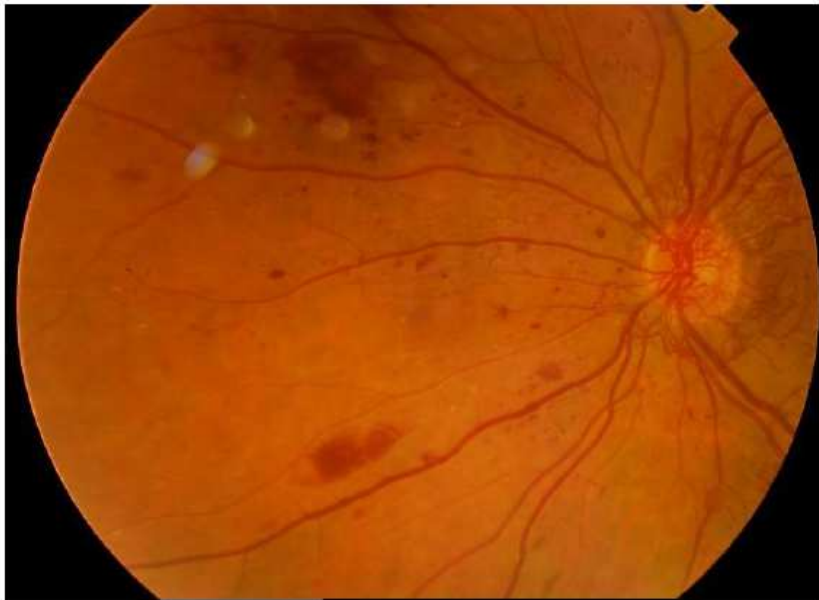# Exsudatieve DRP

- Microaneurysmata
- Bloedingen
- Harde exsudaten
- Oedeem



# Proliferatieve DRP

Cotton wool spots = zachte exsudaten  
Grotere bloedingen  
Occlusie capillairen  
Neovascularisaties (papil, retina, iris)



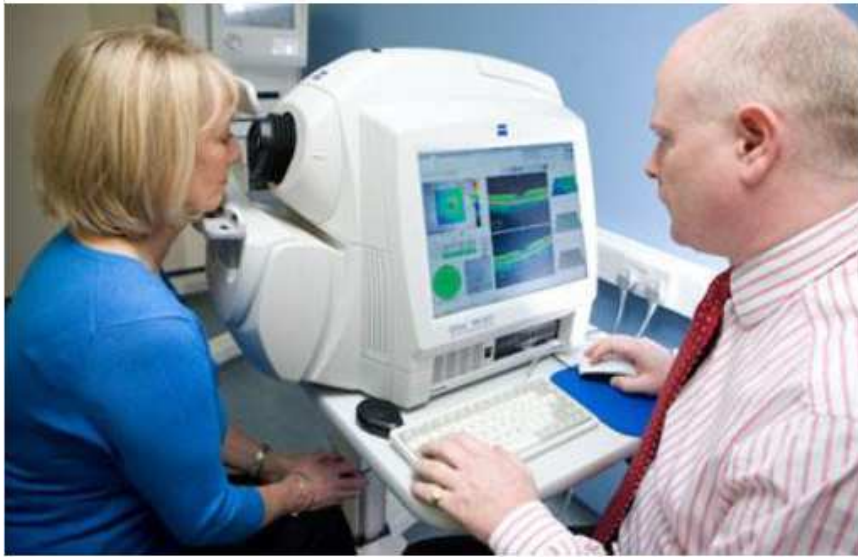# Aanvankelijk geen klachten

Visus is goed zolang de macula  
niet aangedaan is!

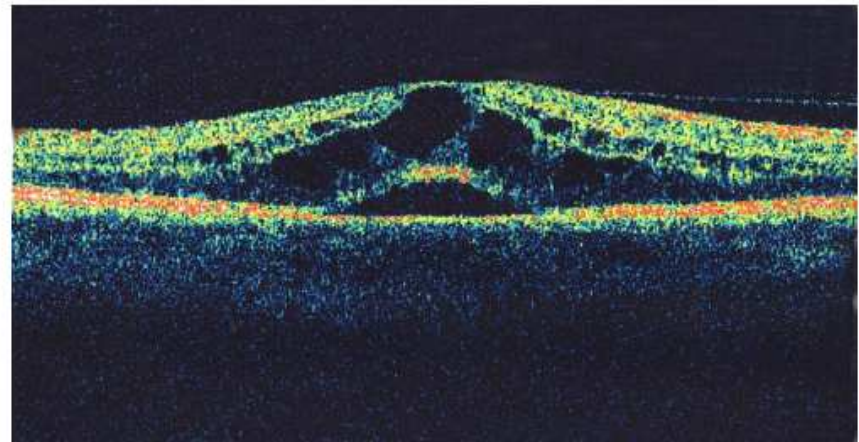
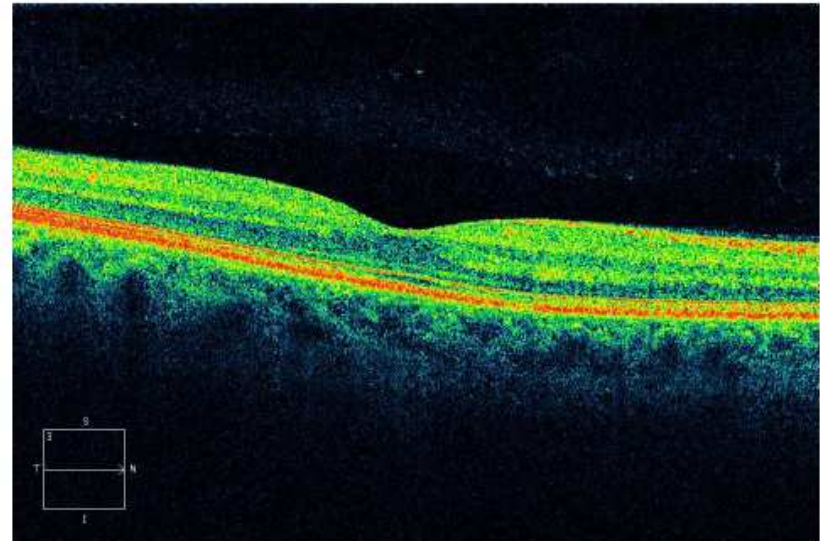
# Oorzaak visusdaling bij DRP

- Maculaoedeem
- Macula ischemie
- Glasvochtbloeding
- Ablatio retinae
- Neovasculair glaucoom

# Macula oedeem belangrijkste oorzaak visusdaling bij DRP



OCT scan



Indicatie behandeling = visusdaling,  
cq als macula bedreigt wordt

- Anti- VEGF
- Lasercoagulatie
- Vitrectomie

# Visusbedreigende Retinopathie

- Neovascularisaties (papil, retina,iris)
- **MACULAOEDEEM**





Lasercoagulatie

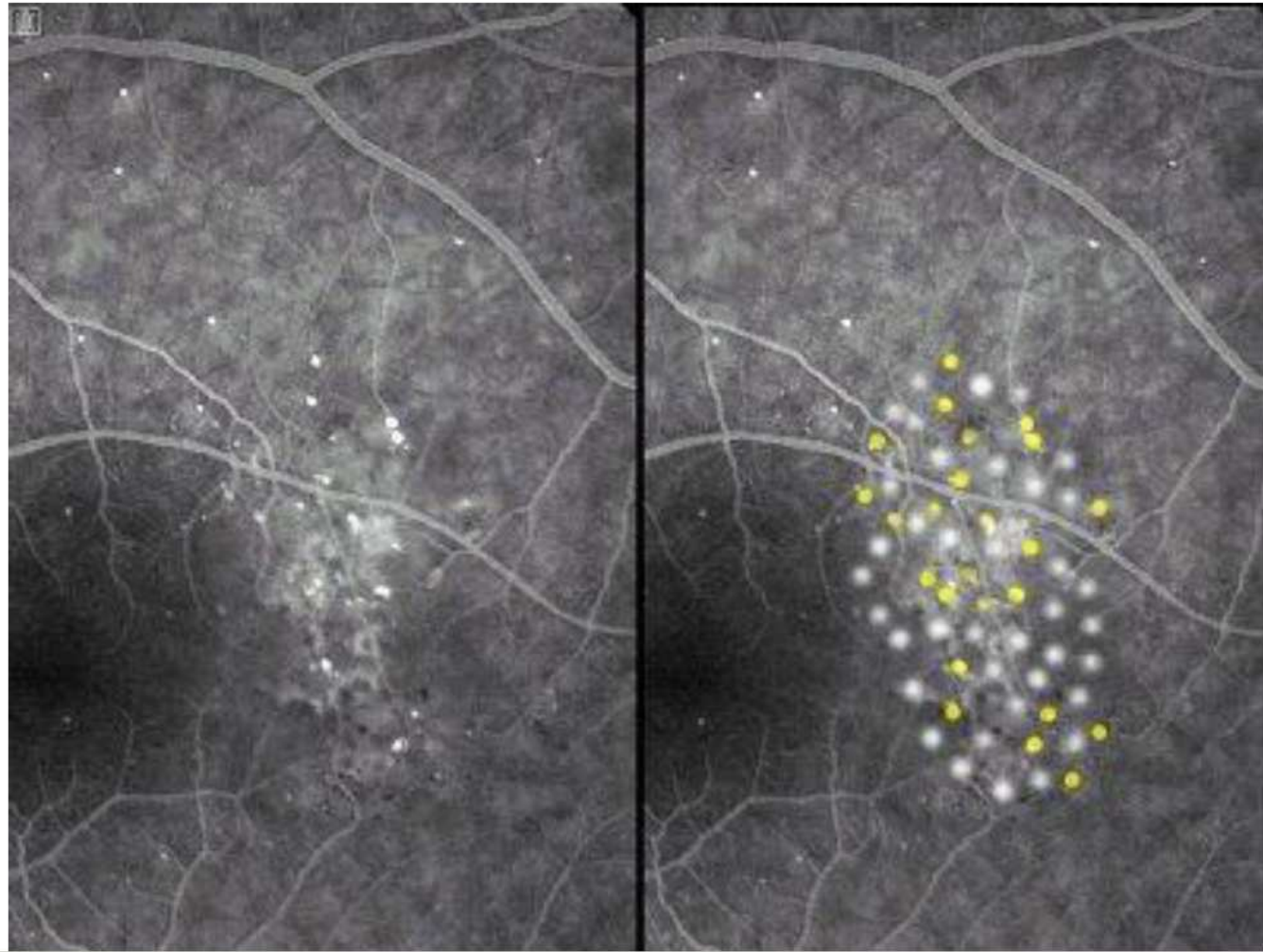
A fundus photograph of a retina showing laser coagulation treatment. The image displays the optic disc on the left, with a network of retinal vessels. Numerous small, dark, circular laser scars are visible across the retina, particularly in the peripheral and mid-peripheral regions. The overall color is a reddish-orange, typical of fundus photography.

Effect: regressie neovascularisatie

# Bijwerkingen PAN retinale lasercoagulatie

- Gezichtsveld beperking
- Donkerzien stoornis

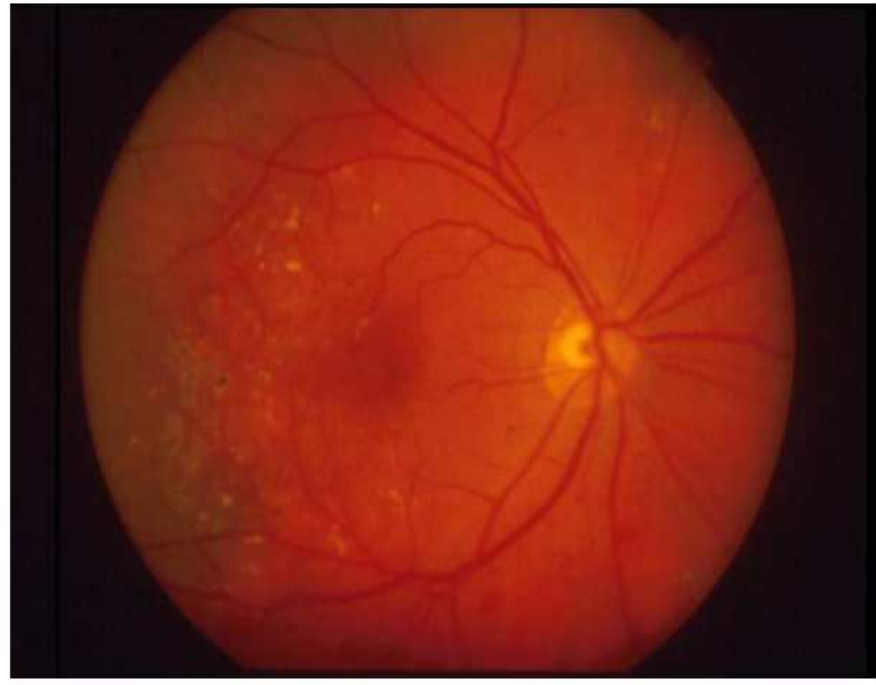
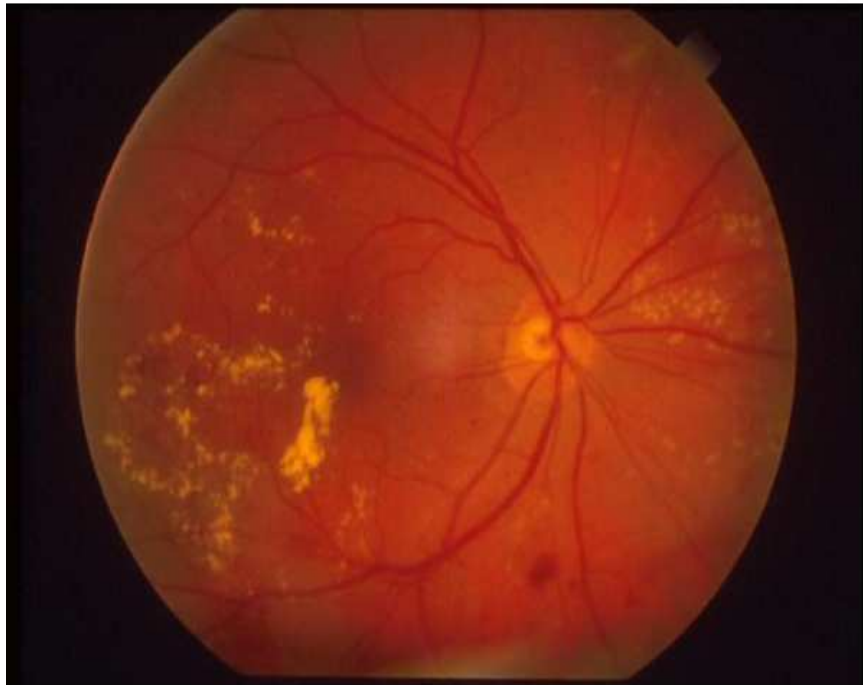# Lasercoagulatie bij maculaoedeem



# Lasercoagulatie bij maculaoedeem

Alle microaneurysmata zijn gecoaaguleerd

3-4 maanden na de laser zijn de harde exsudaten geresorbeerd

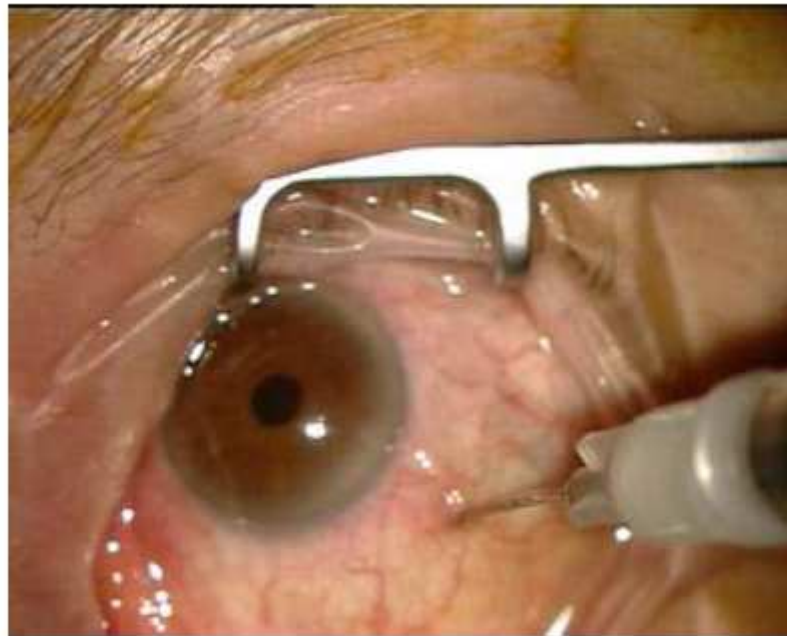


# Diffuus maculaoedeem anti VEGF injectie intravitreaal

Bevacizumab Avastin

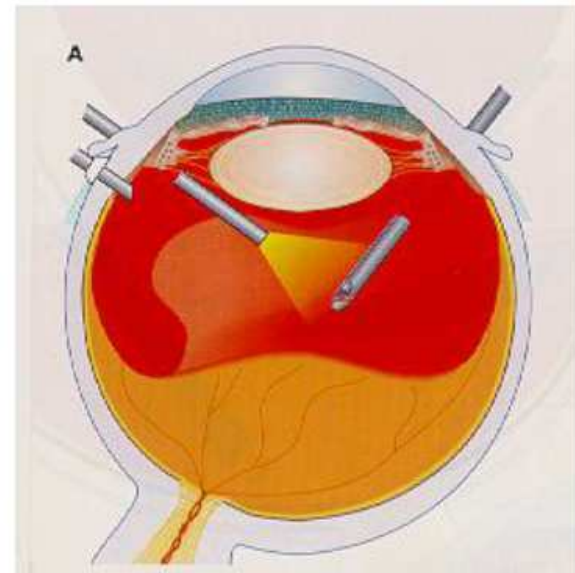
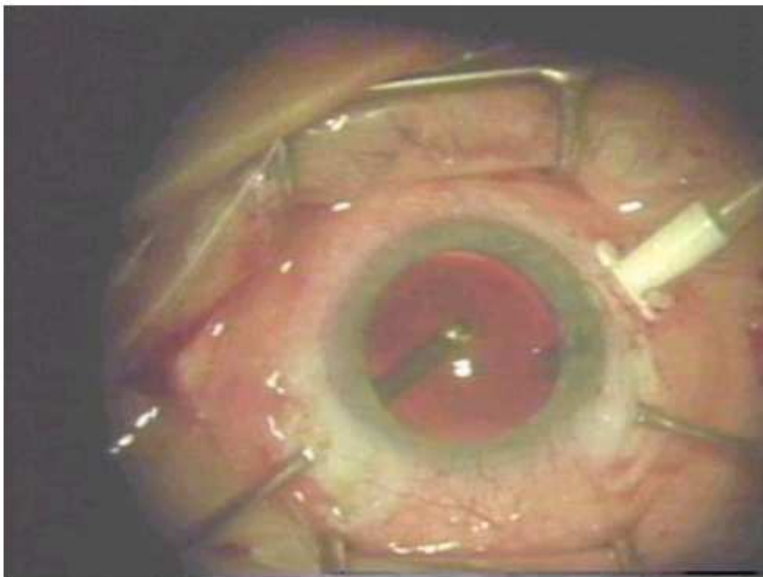
Ranizumab Lucentis

Aflibercept Eylea

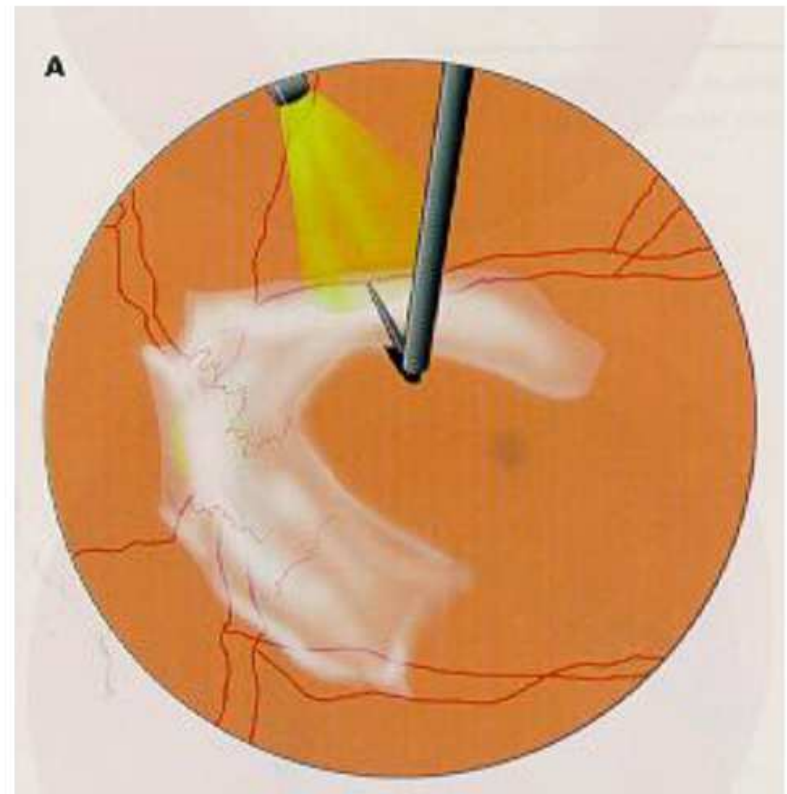
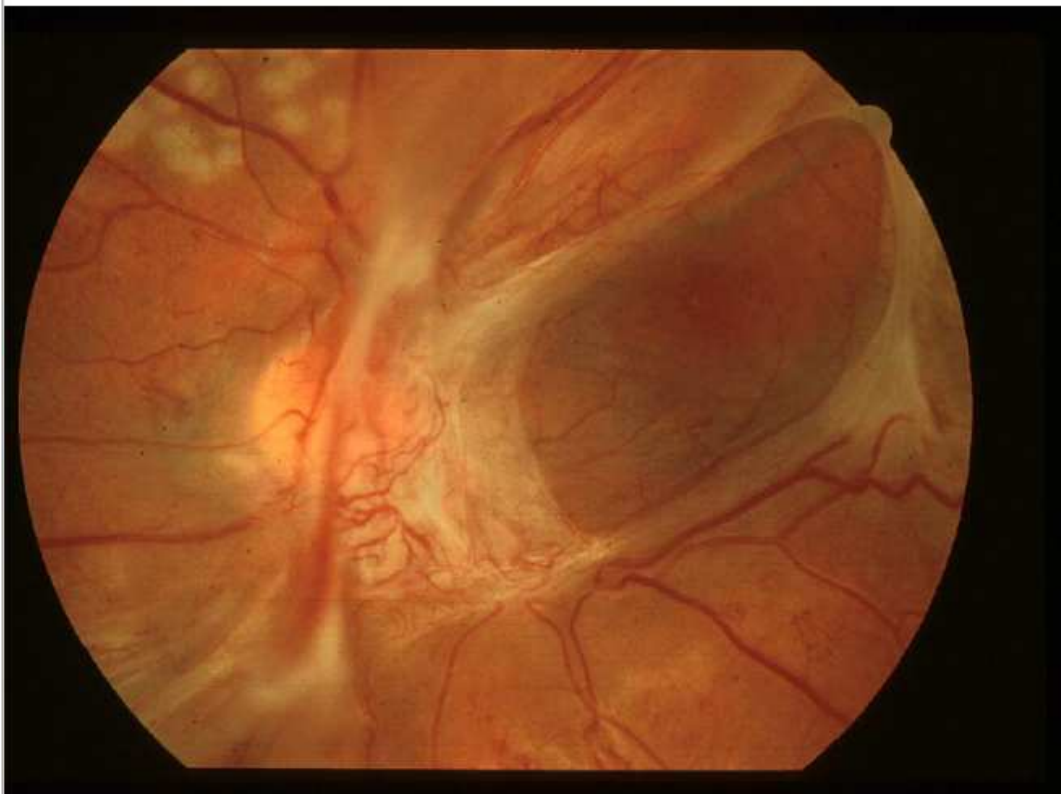


# Vitrectomie

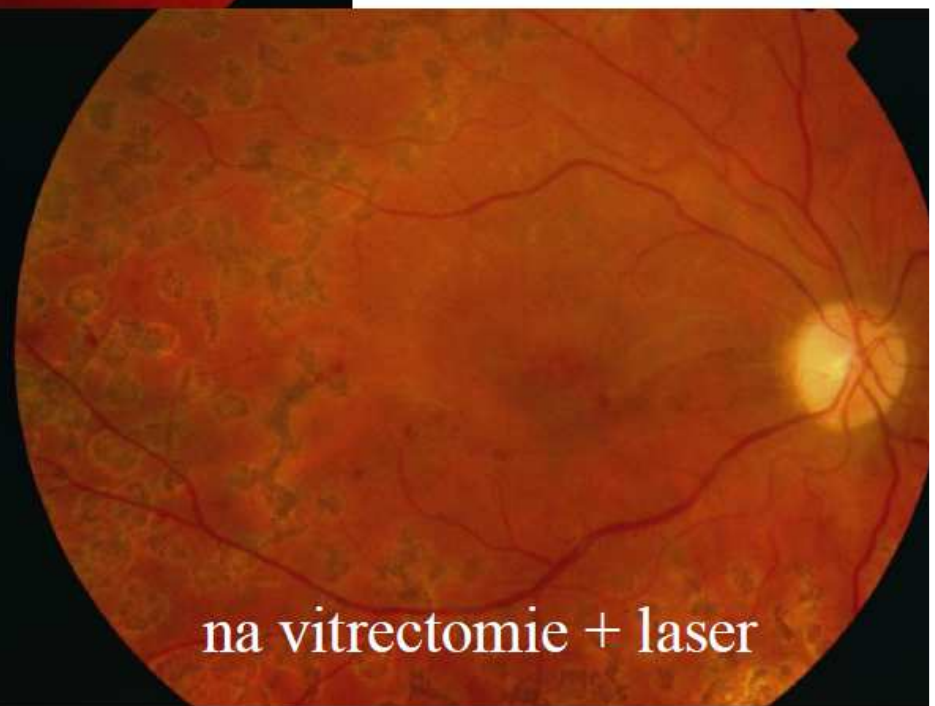
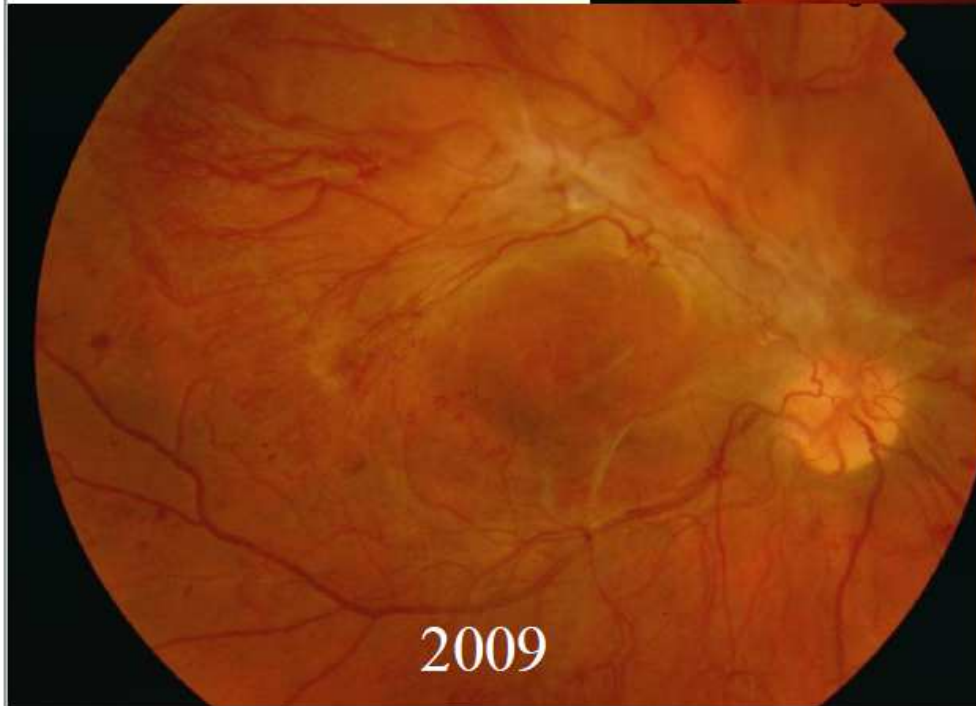
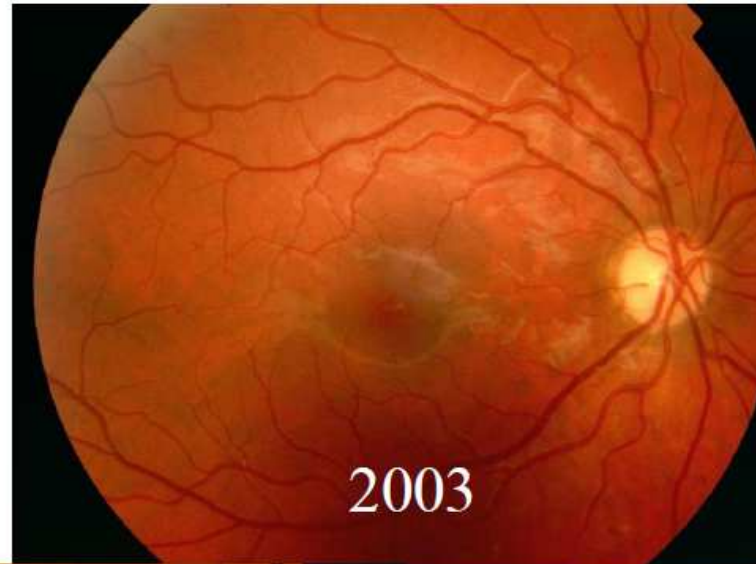
- Niet ophelderende glasvochtbloeding
- Tractie aan de macula
- Netvliesloslating (door tractie)



# Vitrectomie



# Gedurende 17 jaar DM type I





# risicofactoren

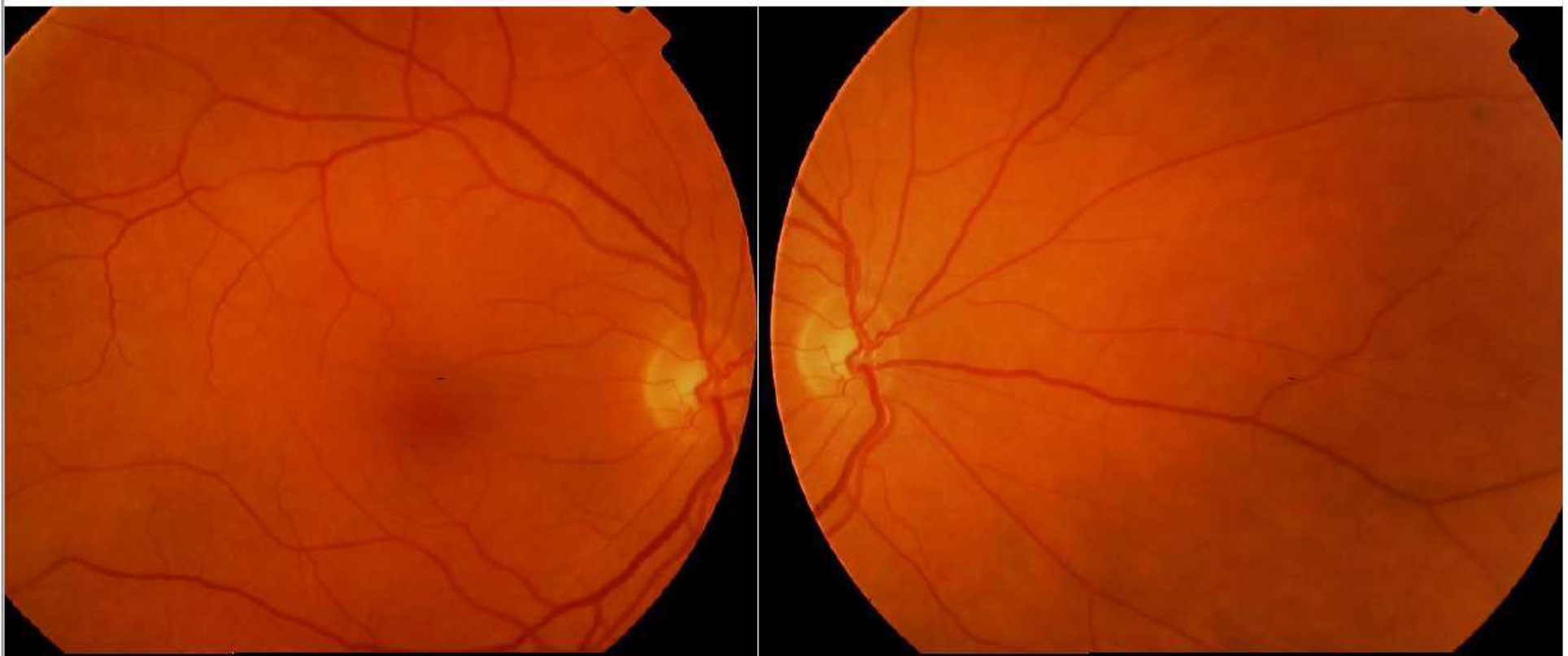
- Duur diabetes mellitus
- Slechte bloedsuikerregulatie
- Hypertensie
- Overgewicht
- Zwangerschap
- Snelle, scherpe daling bloedsuikers
- Slechte nierfunctie

# Is slechtziendheid door DRP te voorkomen?

- Tijdig en adequaat behandelen
  
- Screenen

# Fotoscreening

## 2 standaard foto's per oog



## Take home message

begin stadium drp geen klachten

effect van late behandeling gering

alle patiënten met diabetes mellitus  
screenen op diabetische retinopathie